

## PRIMARY RETROPERITONEAL BRONCHOGENIC CYST MIMICKING HYDATID CYST – A CASE REPORT

Ashwani Kumar<sup>1</sup>, Pankaj K Garg<sup>2</sup>, Paras K Pandove<sup>3</sup>, Vijay K Sharda<sup>4</sup>, Parul K Garg<sup>5</sup>, Manjeet Singh Bal<sup>6</sup>, Nikhil Mahajan<sup>7</sup>

### ABSTRACT

Bronchogenic cyst are generally found in mediastinum, particularly posterior to carina, but they rarely occur in unusual sites such as skin, subcutaneous tissue, pericardium and retroperitoneum. Bronchogenic cysts can in fact mimic hydatid cysts particularly in endemic areas like India. We report a case of retroperitoneal bronchogenic cyst mimicking a hydatid cyst in retroperitoneal location.

A 45-year-old man was admitted to our hospital with complaint of pain in right iliac fossa. CECT of abdomen showed abdominopelvic retroperitoneal cystic mass lateral to right psoas muscle and anterior to right iliacus muscle. CECT findings were suggestive of hydatid cyst. Under general anesthesia, exploratory laprotomy and excision of the retroperitoneal cyst was done. Histopathological findings were that of bronchogenic cyst.

Most bronchogenic cysts have a benign nature, but malignant changes have also been reported. Therefore, if a cystic tumor in the abdomen is suspected during preoperative diagnosis, a bronchogenic cyst should be considered in the differential diagnosis. Although most are asymptomatic, excision is recommended to establish a definite diagnosis, alleviate any symptoms and to remove the documented risk of malignant transformation.

**KEYWORDS :** Retroperitoneum; Bronchogenic cyst; Hydatid cyst.

### INTRODUCTION

Bronchogenic cysts are rare benign congenital anomalies that result from abnormal budding of the developing tracheobronchial tree, with separation of the buds from the normal airways [1]. Bronchogenic cysts are lined by respiratory epithelium with bronchial glands, smooth muscle, and cartilage.

Bronchogenic cysts frequently occur in the thorax. Apart from the thorax, they rarely occur at sites such as skin, subcutaneous tissue and pericardium, but subdiaphragmatic bronchogenic cysts are particularly uncommon with ones in the retroperitoneum being distinctly rare. Retroperitoneal bronchogenic cysts are usually asymptomatic, unless they become secondarily infected, perforated, or large enough to compress adjacent organs [2]. A case of adenocarcinoma arising in a retroperitoneal bronchogenic cyst has also been reported [3].

On CECT bronchogenic cysts appear as spherical or oval masses with smooth outlines and are usually unilocular and noncalcified [4,5]. Bronchogenic cysts can in fact mimic hydatid cysts. However, the CT density reading may be higher, comparable to that of soft tissue, which can create other problems in diagnosis [6]. Here we are presenting a rare case of retroperitoneal bronchogenic cyst, mimicking as hydatid cyst in preoperative evaluation.

### CASE SUMMARY

A 45 year old man was admitted to surgery department at Rajindra hospital with complaint of pain in right iliac fossa. Patient was clinically examined and found to have 8cm x 7cm mass in right iliac fossa and right lumbar region. USG abdomen revealed a well defined predominantly anechoic cystic, lobulated bilocular mass measuring approximately 12.3cm x 8.0cm x 6.0cm in size in right lumbar region. It had internal echoes as well as faintly echogenic aggregates. The mass inferiorly extended upto the level of right iliacus muscle. Radiologist reported that it could be retroperitoneal cystic mass. X-ray of the chest was normal and the liver scan showed no space occupying lesion. CECT of abdomen showed abdominopelvic retroperitoneal cystic mass lateral to right psoas muscle and anterior to right iliacus muscle (Figure 1). Foci of calcification were seen within wall of mass. Radiologist reported

it as hydatid cyst. However serology for echinococcus antibodies IgG revealed normal value.

Under general anesthesia exploratory laprotomy and excision of the retroperitoneal cyst was done. Intraoperatively, a 12cm x 10cm cystic mass was present lateral to right psoas muscle and anterior to right iliacus muscle (Figure 2). Tip of appendix was adherent to the mass. Mass was not adherent to any other organ. Appendectomy was also performed.

On section the cystic mass was bilocular containing thick mucoid fluid with thin membranous wall of even thickness, while the internal surface was uniformly smooth (Figure 3). Histo-pathological examination revealed cyst wall lined by stratified columnar epithelium with some goblet cell, focal dystrophic calcification, fibro-connective tissue, some necrosis and non specific inflammatory infiltrate (Figure 4). These features were suggestive of retroperitoneal mucoid mass with possibility of bronchogenic cyst.

## DISCUSSION

Bronchogenic cysts are rare abnormalities and usually arise from the ventral portion of the primitive foregut. During the period of embryogenesis, the primitive foregut develops into respiratory and alimentary systems in the fourth week. Initially both the lining cells in the oesophagus and the trachea are ciliated columnar before separation of the tracheoesophageal fold. After formation of the tracheoesophageal septum, the oesophagus rapidly elongates. Any abnormality in this stage of embryogenesis may lead to malformation of the oesophagus and the trachea. Bronchogenic cysts arise from an abnormal budding of the tracheobronchial analog of the primitive foregut during the 3rd to 7th weeks of development. When attachment to the primitive foregut persists, the cyst is usually associated with the tracheobronchial tree or the oesophagus. If complete separation occurs, the cyst may occur in other unusual locations, presumably by migration.[7] A retroperitoneal location is exceptionally unusual. Although the exact mechanism is unknown. Sumiyoshi et al hypothesized that the thoracic and abdominal cavities are linked by the pericardioperitoneal canal in an early embryonic stage. When the canal is divided into 2 respective

cavities by fusion of the pleuroperitoneal membranes (the future component of the diaphragm) at the end of the 6th week of intrauterine life, abnormal buds of the tracheobronchial tree are pinched off by these membranes and migrate into the abdomen, resulting in a retroperitoneal bronchogenic cyst[8]. Another less likely alternative hypothesis explains aberrant differentiation of foregut-derived cysts originating intra-abdominally.[7]

On this embryologic basis, although most bronchogenic cysts are found most frequently in the posterior mediastinum adjacent to the tracheal bifurcation, they can occasionally occur in the subdiaphragmatic area. The majority (82%) of these cysts are located in a triangle behind the stomach defined by the midline, the splenic vein inferiorly, and the spleen/diaphragm superior/posteriorly.[9] Rarely, the cysts have occurred in other locations, including cutaneous [10] and subcutaneous tissues [11], neck [12], pericardium [13], diaphragm [14], abdomen [7], and the intramedullar part of the spine [15]. They have also been reported to extend from the mediastinum through the diaphragm into the abdomen as dumbbell cysts [16]. Menike et al. reviewed 38 cases of subdiaphragmatic bronchogenic cysts and reported that 82% and 63 % of them were located in left side of the body and retroperitoneal lesions, respectively [17].

Because of the rarity of retroperitoneal bronchogenic cysts, their imaging features have seldom been described [2]. Making a preoperative diagnosis of retroperitoneal bronchogenic cyst is very difficult. These masses are divided into neoplastic (cystic lymphangioma, mucinous cystadenoma, cystic teratoma, cystic mesothelioma, mu"llerian cyst, epidermoid cyst, tailgut cyst, bronchogenic cyst, cystic change in solid neoplasms, pseudomyxoma retroperitonei, perianal mucinouscarcinoma) and nonneoplastic (pancreatic pseudocyst, nonpancreatic pseudocyst, lymphocele, urinoma, hematoma, hydatid cyst) lesions. Microscopically, the cysts contain one or more of the tissues that are normally found in the trachea or bronchi. Characteristically, they are lined with ciliated, pseudostratified, columnar epithelium. In portions of the cyst, squamous metaplasia may occur, or the epithelium as well as cilia may be

absent. The walls of the cyst consist of fibrous connective tissue, which commonly, but not necessarily, contains glands, hyaline cartilage, smooth muscle, elastic fibres, and nerve trunks, either alone or varying combinations [18].

In our case a preoperative diagnosis of hydatid cyst was made on the basis of CECT scan finding. In hydatid cyst CT scan demonstrates the thickened wall calcifications and intra-cystic fluid content mixed density, with internal septa confer a multilocular appearance. At CT, bronchogenic cysts manifest as rounded, well-circumscribed hypoattenuating cysts without enhancement [1]. They can be misdiagnosed as solid masses because they appear hyperattenuating owing to the protein contents of the lesion. In addition, bronchogenic cysts may have calcifications [2].

In our patient CECT of abdomen was suggestive of retroperitoneal hydatid cyst but serological test for IgG by ELISA, was negative, which is the most sensitive method for diagnosis of human hydatidosis. Although some patients with hydatid disease may have no demonstrable specific immune response. Because the sensitivity of the tests is inversely proportional to the degree of sequestration of antigens within the cyst.[19,20] So on the bases of epidemiological fact and CECT of abdomen preoperative diagnosis of retroperitoneal hydatid cyst was made. However, histopathological examination revealed retroperitoneal bronchogenic cyst.

Most bronchogenic cysts are benign and remain asymptomatic. Infection is a well known complication in these lesions. Malignancy arising in bronchogenic cyst has been reported only rarely, and most occur in the mediastinum and chest. Reported malignancies include adenocarcinoma, squamous cell carcinoma, fibrosarcoma, undifferentiated carcinoma, leiomyosarcoma, embryonal rhabdomyosarcoma, and anaplastic carcinoma [21].

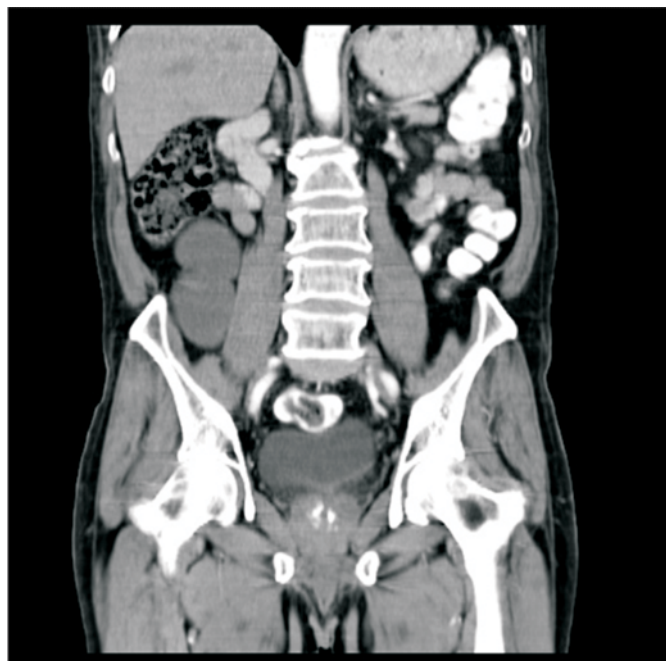The treatment of retroperitoneal bronchogenic cyst is surgical removal via laparoscopy or laparotomy. Although most are asymptomatic, excision is recommended to establish a definite diagnosis, alleviate any symptoms and to remove the documented risk of malignant transformation.

## CONCLUSION

Primary retroperitoneal bronchogenic cyst can

mimic hydatid cyst especially in a developing country like ours where incidence of parasitic diseases is high. More than two-third of all retroperitoneal tumors are malignant however, malignancy arising in bronchogenic cysts is rare, with only one case reported in the literature so far. The recommended treatment is surgical removal for definite diagnosis and symptom relief.

Figure 1 : Abdomen CT scan of patient



Legend 1: CT scan showing abdominopelvic retroperitoneal cystic mass lateral to right psoas muscle and anterior to right iliacus muscle.

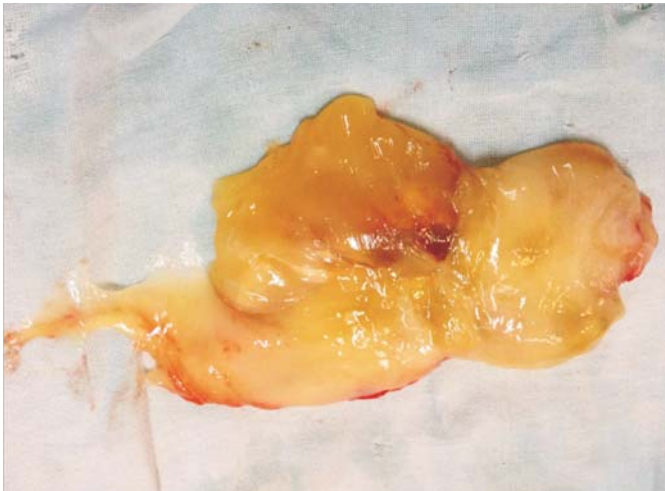
Figure 2—Intra-operative picture

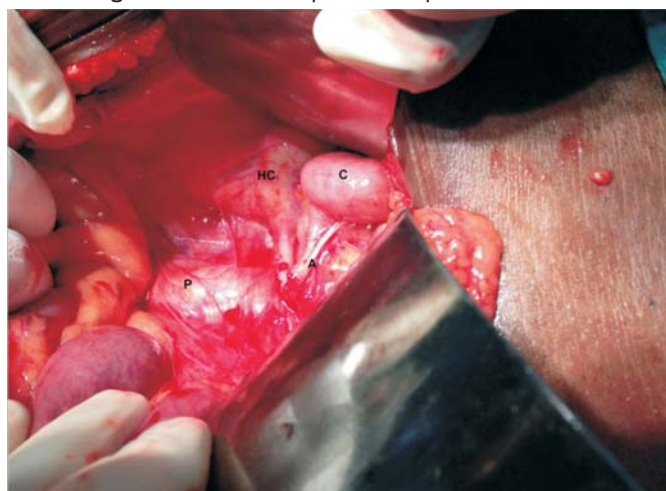

Figure 2: Intraoperative picture showing, a 12cm x 10cm cystic mass, lateral to right psoas muscle and anterior to right iliacus muscle.

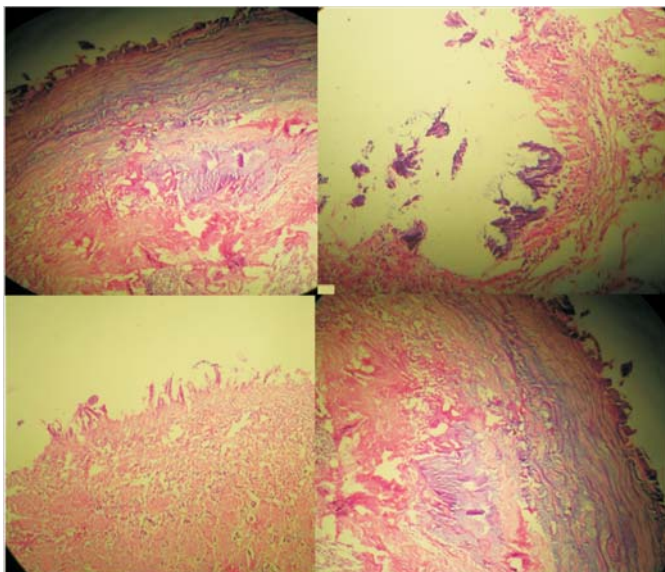


Figure 3 – Macroscopic picture of bronchogenic cyst



**Legend 3:** Cut section showing bilocular cyst containing thick mucoid fluid with thin membranous wall of even thickness, while the internal surface is uniformly smooth.

Figure 4 – Photomicrograph of bronchogenic cyst



**Legend 4:** Photomicrograph showing cyst wall lined by stratified columnar epithelium with some goblet cell, focal dystrophic calcification, fibro-connective tissue, some necrosis and non specific inflammatory infiltrate.

## REFERENCES

1. E. S. Siegelman, B. A. Birnbaum, E. F. Rosato, and J. A. Buckley, "Bronchogenic cyst appearing as a retroperitoneal mass," *American Journal of Roentgenology*, vol. 171, no. 2, pp. 527–528, 1998.
2. Murakami R, Machida M, Kobayashi Y, Ogura J, Ichikawa T, Kumazaki T. Retroperitoneal bronchogenic cyst: CT and MR imaging. *Abdom Imaging* 2000;25:444-447
3. Sullivan SM, Okada S, Kudo M, Ebihara Y. A retroperitoneal bronchogenic cyst with malignant change. *Pathol Int* 1999; 49:338-341
4. R. St-Georges, J. Deslauriers, A. Duranceau et al., "Clinical spectrum of bronchogenic cysts of the mediastinum and lung in the adult," *Annals of Thoracic Surgery*, vol. 52, no. 1, pp. 6–13, 1991.
5. M. Di Lorenzo, P. P. Collin, R. Vaillancourt, and A. Duranceau, "Bronchogenic cysts," *Journal of Pediatric Surgery*, vol. 24, no. 10, pp. 988–991, 1989.
6. L. M. Ramenofsky, L. L. Leape, and R. G. McCauley, "Bronchogenic cyst," *Journal of Pediatric Surgery*, vol. 14, no. 3, pp. 219–224, 1979.
7. Coselli MP, de Ipolyi P, Bloss RS, Diaz RF, Fitzgerald JB. Bronchogenic cysts above and below the diaphragm: report of eight cases. *Ann Thorac Surg* 1987;44:491–494
8. Sumiyoshi K, Shimizu S, Enjoji M, Iwashita A, Kawakami K. Bronchogenic cyst in the abdomen. *Virchows Arch Pathol Anat Histopathol* 1985;408:93–98.
9. Liang MK, Yee HT, Song JW, et al. Subdiaphragmatic bronchogenic cysts: a comprehensive review of the literature. *Am Surg* 2005; 71:1034–1041.
10. Tresser NJ, Dhams B, Berner JJ. Cutaneous bronchogenic cyst of the back: a case report and review of the literature. *Pediatr Pathol* 1994; 14: 207–212.
11. Bagwell CE, Schiffman RJ. Subcutaneous bronchogenic cysts. *J Pediatr Surg* 1988; 23: 993–995.
12. Riquet M, Choubrac P, Molinier H, Carnot F, Debesse B. Kyste tracheogenique aerien cervical: a propos de 2 observations. *Rev Pneumol Clin* 1985; 41: 157–162.

13. Gomes MN, Hufnagel CA. Intrapericardial bronchogenic cysts. *Am J Cardiol* 1975; 36: 817-822.
14. Buddington TW. Intradiaphragmatic cyst. Ninth reported case. *N Engl J Med* 1957; 257: 613-614.
15. Duthel R, Brunon J, Michel D, Boucheron S. Kyste bronchogénique intramedullaire. A propos d'un cas. Discussion du syndrome d'adhésion syndromes. *Neurochirurgie* 1983; 29: 155-160.
16. Amendola MA, Shirazi KK, Brooks J, Agha FP, Dutz W. Transdiaphragmatic bronchopulmonary foregut anomaly: "Dumbbell" bronchogenic cyst. *AJR* 1982; 138: 1165-1167.
17. Menke H, Roher HD, Gabbert H, Schweden F. Bronchogenic cyst: a rare cause of a retroperitoneal mass. *Eur J Surg* 1997;163:311-314
18. Rogers LF, Osmer JC. Bronchogenic cyst: a review of 46 cases. *AJR* 1964; 91: 273-293.
19. Moro P, Schantz P. Echinococcosis: a review. *Int J Infect Dis* 2009 Mar; 13: 125-133.
20. Zhang W, McManus D. Recent Advances in the immunology and diagnosis of echinococcosis. *FEMS Microbiol Immunol Mcd* 2006, 47: 24-41
21. Sullivan SM, Okada S, Kudo M, Ebihara Y. A retroperitoneal bronchogenic cyst with malignant change. *Pathol Int* 1999; 49:152-155.

1. **Ashwani Kumar**  
Associate Professor  
Department of Surgery  
Rajindra Hospital / Government Medical College,  
Patiala – 147001, Punjab
2. **Pankaj K Garg**  
Department of Surgery  
Rajindra Hospital / Government Medical College  
Patiala – 147001, Punjab
3. **Paras K Pandove**  
Department of Surgery  
Rajindra Hospital / Government Medical College  
Patiala – 147001, Punjab

4. **Vijay K Sharda**  
Department of Surgery  
Rajindra Hospital / Government Medical College  
Patiala – 147001, Punjab
5. **Parul K Garg**  
Department of Pathology,  
Rajindra Hospital / Government Medical College  
Patiala – 147001, Punjab
6. **Manjeet Singh Bal**  
Department of Pathology,  
Rajindra Hospital / Government Medical College  
Patiala – 147001, Punjab
7. **Nikhil Mahajan**  
Department of Surgery  
Rajindra Hospital / Government Medical College  
Patiala – 147001, Punjab